

Clinical Application of the Essix III Corrector

PHILIPPE AMAT, DDS, DOrth

Various appliances have been designed to re-establish anterior functional guidance in treatment of pseudo-Class III malocclusion.¹⁻⁴ The first step is to eliminate prematurities that cause the forward mandibular slide. Once the bite has been corrected, the patient needs corrective breathing and myofunctional therapy to ensure that the dental results remain stable.

Sheridan and colleagues have described the application of Essix* devices for passive retention and minor tooth movement.⁵⁻⁷ This article demonstrates the Essix III Corrector, a new Essix-based appliance developed for early treatment of anterior crossbite.

Appliance Fabrication

The Essix III Corrector is fabricated and delivered as follows:

1. Construct a full-arch Essix appliance by thermoforming an .040" Essix Type A+* plastic sheet over a working cast of the mandible (Fig. 1). Type A+ plastic is a modified poly(ethylene-coterephthalate) resin that allows acrylic to be added with no risk of material breaking away from the appliance.
2. Build up an inclined plane of orthodontic acrylic over the anterior teeth. Prepare the surface

*Registered trademark of Raintree Essix, Inc., 6448 Parkland Drive, Sarasota, FL 34243; www.essix.com.

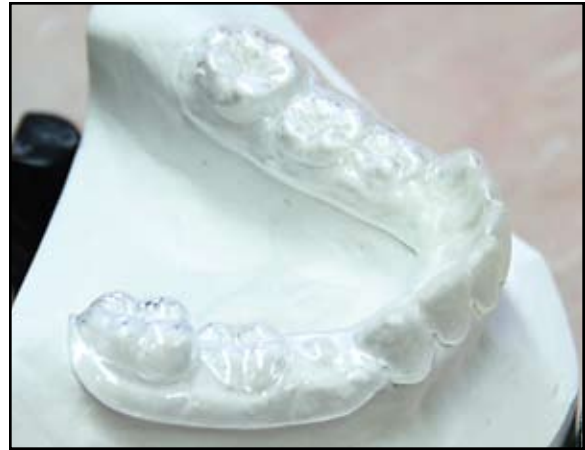

Fig. 1 Essix Type A+ plastic sheet thermoformed over working cast and trimmed to form base of Essix III Corrector.

of the Essix sheet by roughening it where the inclined plane will be built. Paint a cold-cure acrylic monomer over the roughened area and allow it to dry. Paint a second coat of acrylic liquid over the first, repeating the process of applying powder and liquid (Fig. 2A) until the desired size and shape of the final plane are achieved. As the patient bites down, the finished appliance should contact only the maxillary teeth to be moved (Fig. 2B). Verify the fit of the appliance in the mouth.

Instruct the patient to wear the Corrector 24 hours a day except at meals. During subsequent visits, adjust the contact points of the plane as the maxillary incisors move toward their proper positions. Use articulating paper to ensure that the plane contacts only the maxillary teeth that are being moved, adding or removing acrylic as indicated.

Case 1

A 10-year-old girl in the mixed dentition displayed an anterior crossbite with the teeth in maximum intercuspation, but a greatly reduced



Dr. Amat is in the private practice of orthodontics at 19 place des Comtes du Maine, 72000 Le Mans, France; e-mail: amatph@noos.fr.



Fig. 2 A. Inclined plane built up through successive applications of acrylic monomer liquid and powder. B. Process repeated until inclined plane allows contact only with maxillary teeth that require movement.

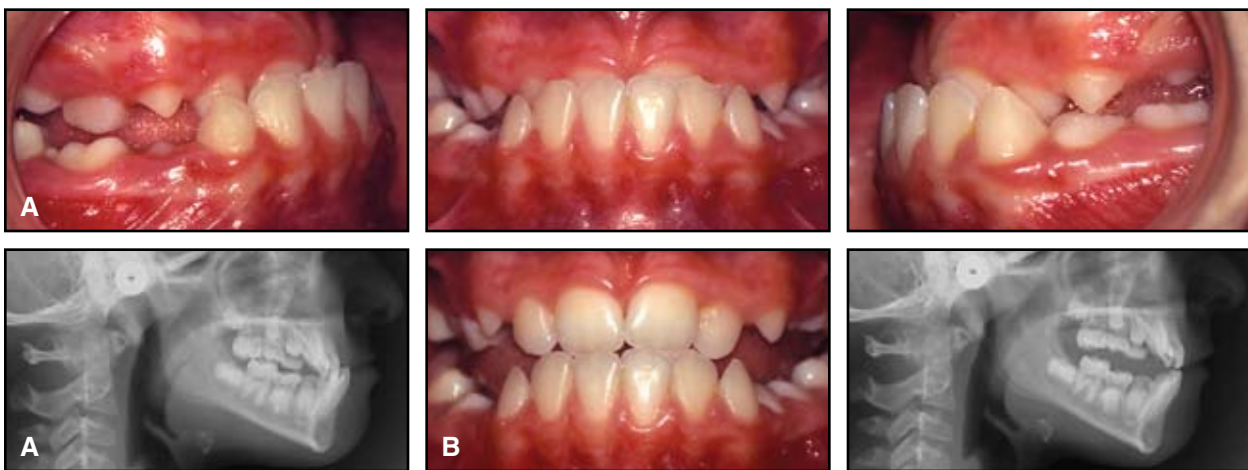


Fig. 3 Case 1. A. 10-year-old female in mixed dentition showing anterior crossbite with teeth in maximum intercuspation before treatment. B. Anterior crossbite reduced to end-to-end with teeth in centric occlusion.

crossbite with the teeth in centric relation (Fig. 3). Delaire analysis indicated a prognathic maxilla with dentoalveolar retrusion, a slight lingual inclination of the maxillary incisors, and a moderate labial inclination of the mandibular incisors (Fig. 4).

An Essix III Corrector was fabricated, and the patient was instructed to wear it full-time except during meals (Fig. 5). After 10 weeks, the anterior crossbite had been corrected (Fig. 6A). The patient continued to wear the appliance at night for another four weeks while receiving myofunctional and breathing reeducation therapy. At the end of the retention period, she discontinued use of the Essix III Corrector entirely. Intraoral photographs taken one month (Fig. 6B) and four months (Fig. 6C) after cessation of appliance wear showed progressive disappearance of the lateral open bites and reinforcement of anterior guidance. Fifteen months after retention, the patient's occlu-

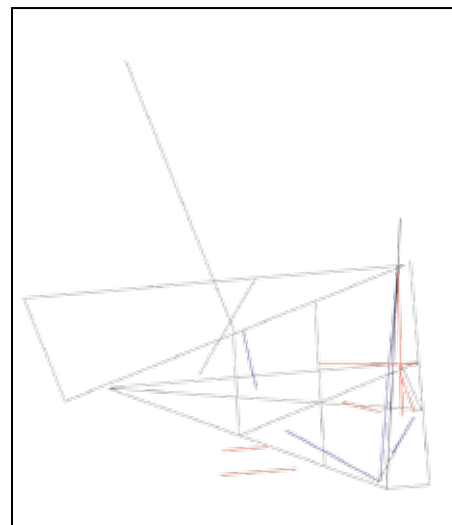


Fig. 4 Case 1. Delaire analysis shows prognathic maxilla with dentoalveolar retrusion, slight lingual inclination of maxillary incisors, and moderate labial inclination of mandibular incisors.

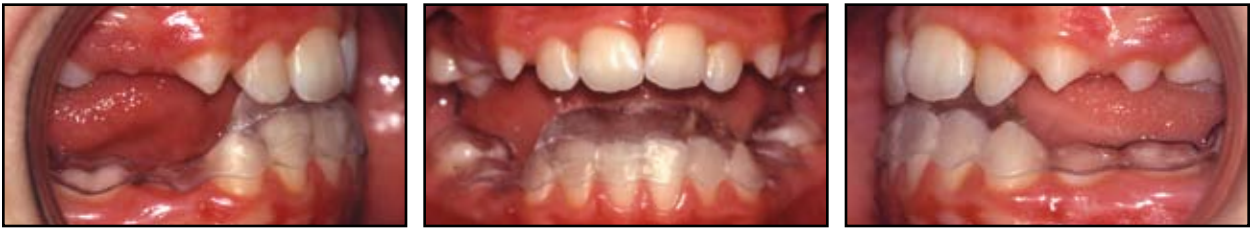

Fig. 5 Case 1. Essix III Corrector in place, with only maxillary incisors making contact.

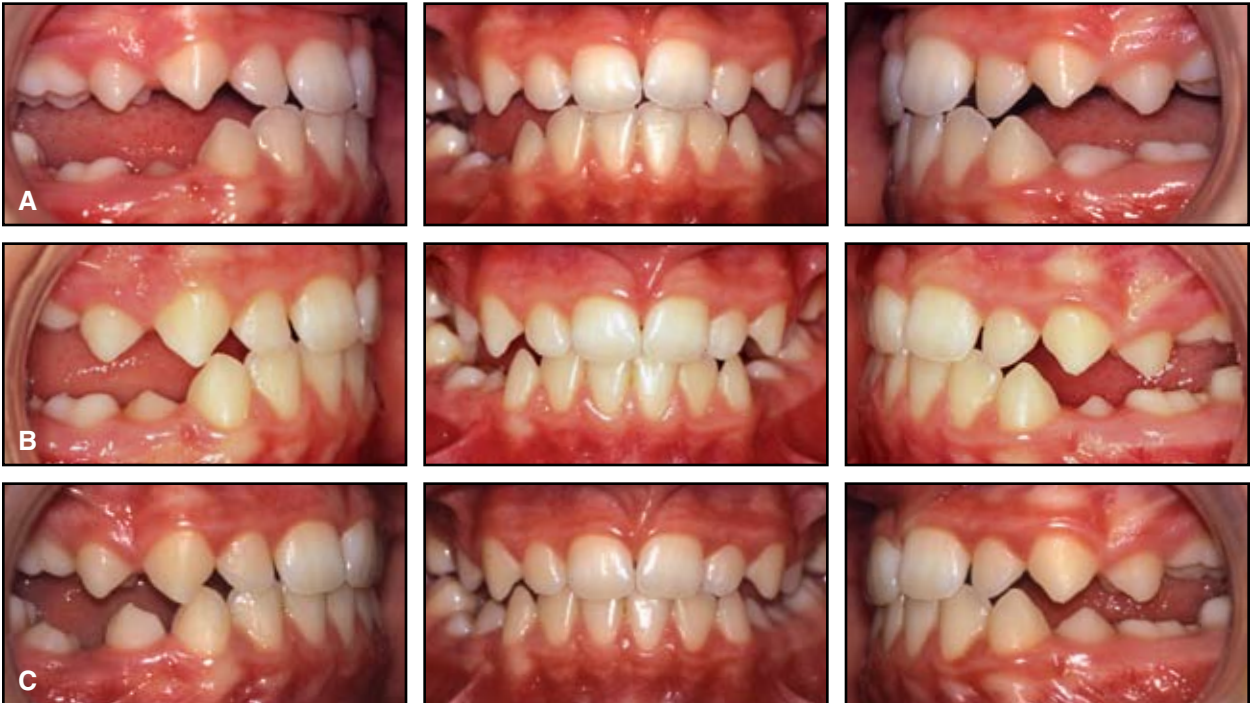

Fig. 6 Case 1. A. Anterior crossbite correction after 10 weeks of full-time Essix III Corrector use. B. One month after cessation of appliance wear. C. Another three months later.

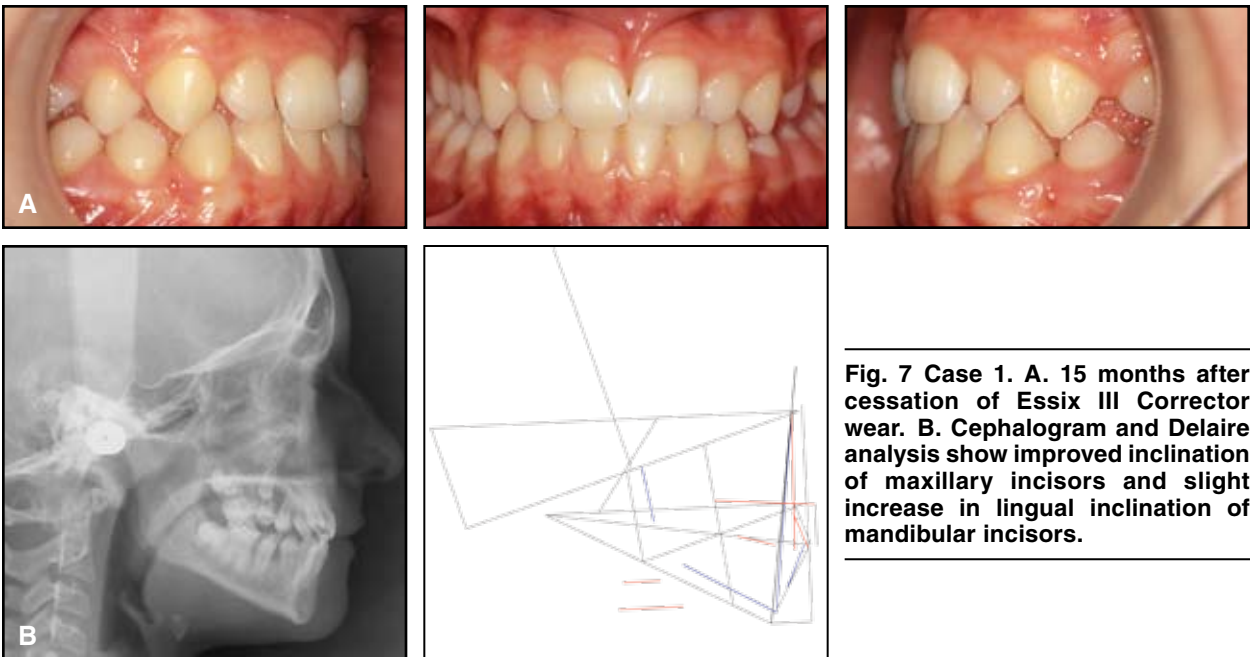


Fig. 7 Case 1. A. 15 months after cessation of Essix III Corrector wear. B. Cephalogram and Delaire analysis show improved inclination of maxillary incisors and slight increase in lingual inclination of mandibular incisors.

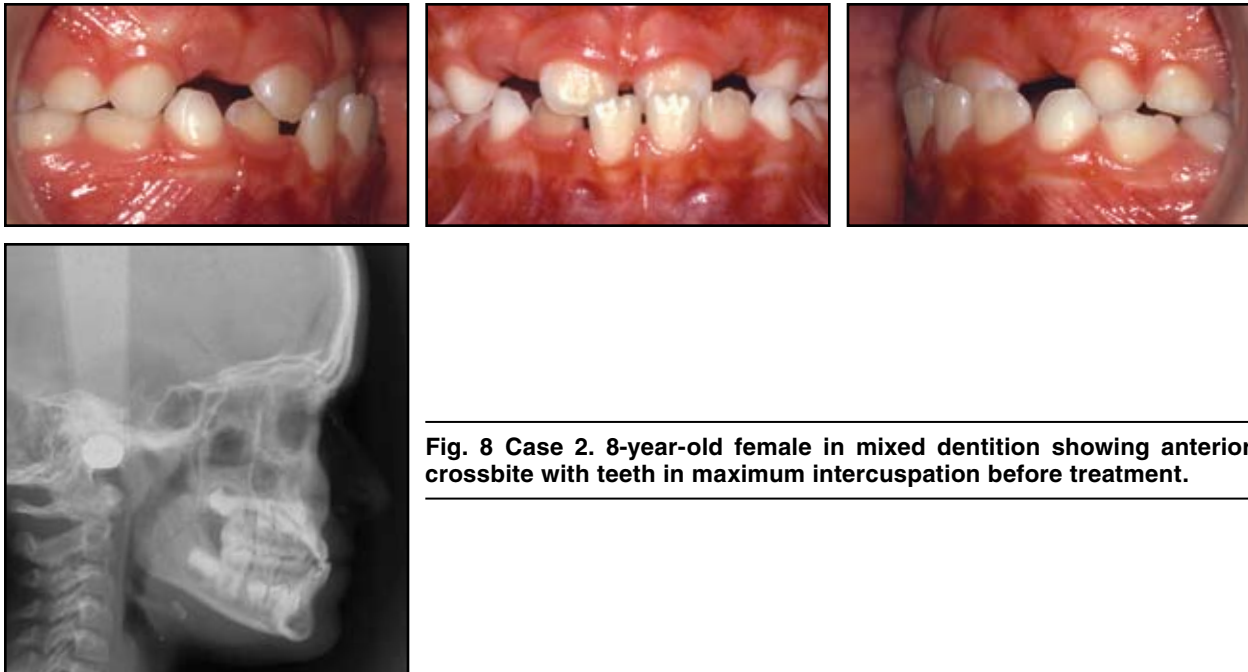


Fig. 8 Case 2. 8-year-old female in mixed dentition showing anterior crossbite with teeth in maximum intercuspation before treatment.

sion was stable and functioning well, anterior guidance had been restored by improvement of the maxillary incisor inclination, and the lingual inclination of the mandibular incisors had slightly increased (Fig. 7).

Case 2

The anterior teeth of this 8-year-old girl in the mixed-dentition stage were in crossbite with the teeth in maximum intercuspation, but end-to-end in centric relation (Fig. 8).

Her anterior crossbite was resolved after she wore the Essix III Corrector continuously for six weeks, except during meals (Fig. 9). She then wore the appliance at night for another two weeks while she received myofunctional therapy, after which appliance wear was discontinued. Four months later, the occlusion remained Class I with functional anterior guidance (Fig. 10).

Conclusion

The Essix III Corrector has the advantages of being virtually invisible, easy and comfortable

to wear, and readily removable at mealtime, and it does not impede speech. Because the success of all removable appliances depends on patient compliance, the acceptance rate of the Essix III Corrector is one of its principal assets.

ACKNOWLEDGMENT: The author thanks Dr. Jay Weiss for his assistance with the English translation of this article.

REFERENCES

1. Rinchuse, D.J. and Rinchuse, D.J.: Active tooth movement with the Essix appliance, *J. Clin. Orthod.* 31:109-112, 1997.
2. Croll, T.P. and Helpin, M.L.: Simplified anterior crossbite correction using a bonded compomer biteplane, *J. Clin. Orthod.* 36:356-358, 2002.
3. Giancotti, A.; Romanini, G.; and Docimo, R.: Early treatment of anterior crossbite with an Essix-based appliance, *J. Clin. Orthod.* 38:161-164, 2004.
4. Tzatzakis, V. and Gidarakou, I.: Correction of anterior crossbite using occlusal build-ups, *J. Clin. Orthod.* 41:393-397, 2007.
5. Sheridan, J.J.; LeDoux, W.; and McMin, R.: Essix appliances: Minor tooth movement with divots and windows, *J. Clin. Orthod.* 28:659-663, 1994.
6. Sheridan, J.J.; McMin, R.; and LeDoux, W.: Essix thermosealed appliances: Various orthodontic uses, *J. Clin. Orthod.* 29:108-113, 1995.
7. Amat, P. and Sorel, O.: Entretien avec John J. Sheridan, *Rev. Orthop. Dentofac.* 38:123-140, 2004.

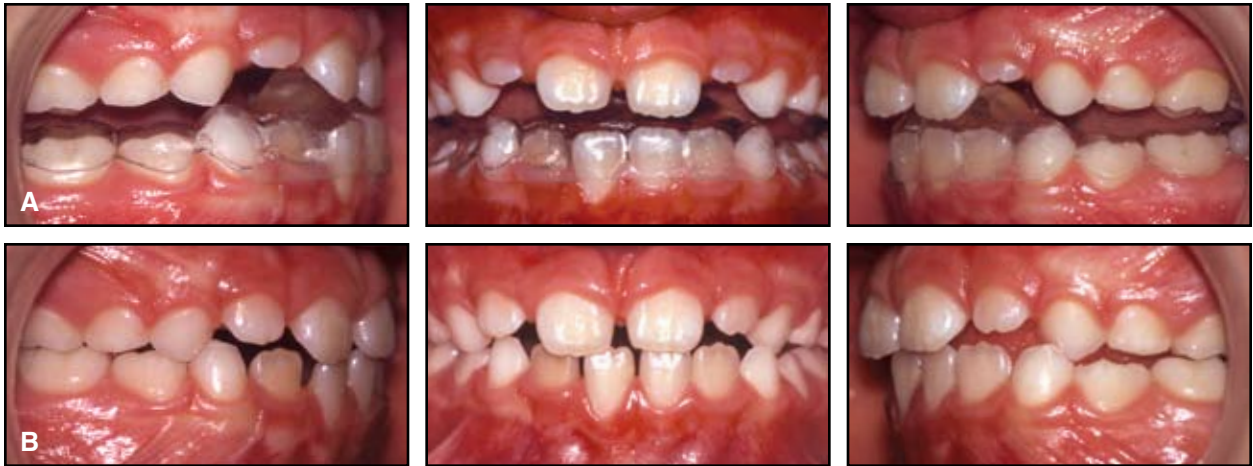

Fig. 9 Case 2. A. Essix III Corrector in place. B. After six weeks of treatment.

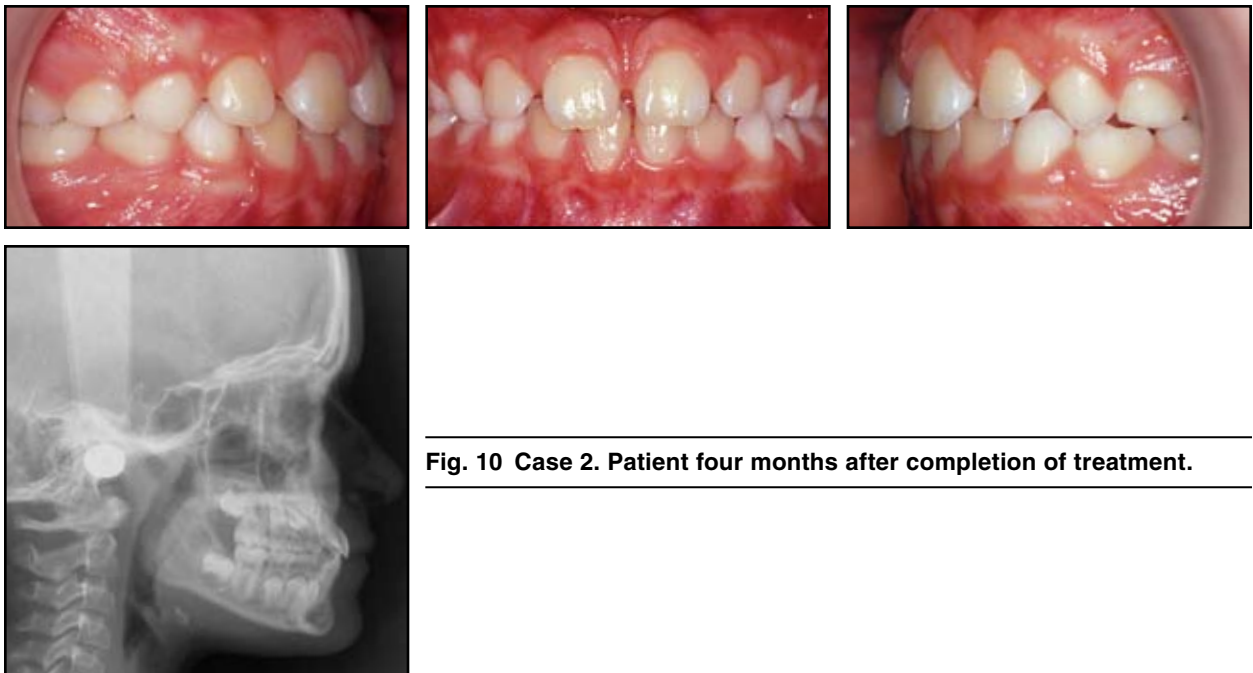


Fig. 10 Case 2. Patient four months after completion of treatment.